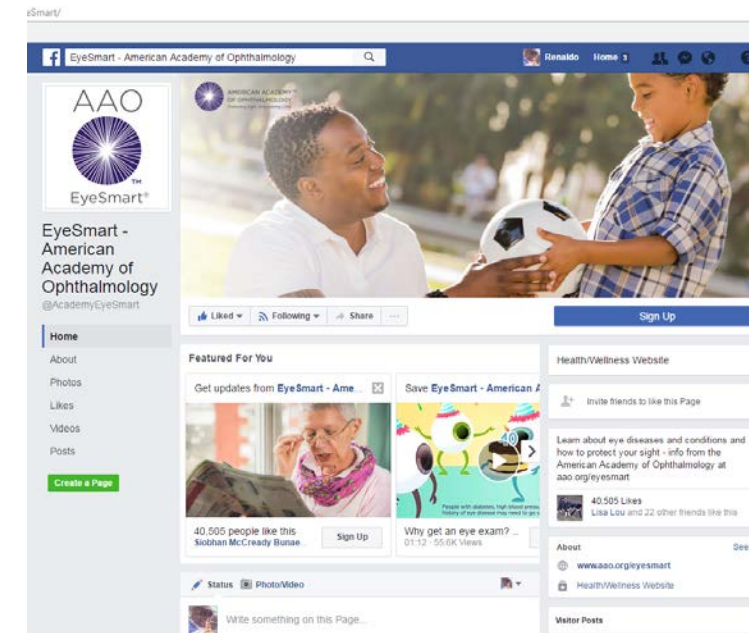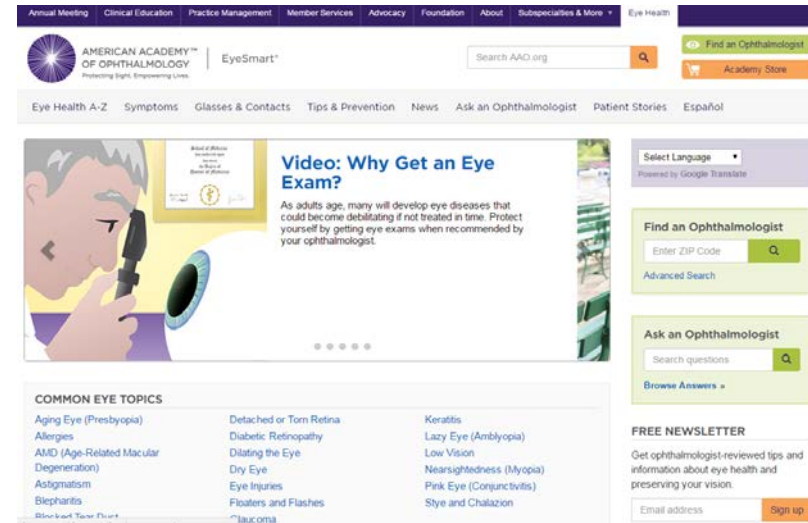


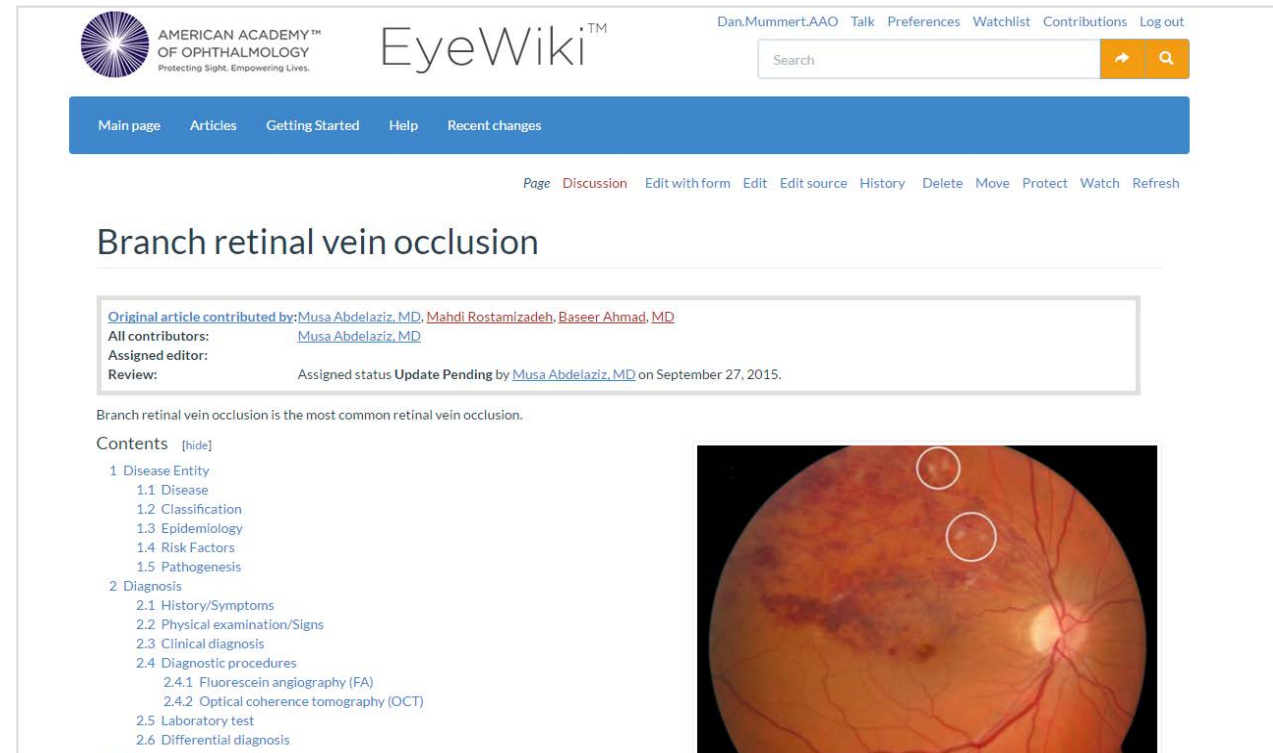
# EyeSmart® Overview

- Academy's primary public communications channel
  - Website, social media and YouTube
- Educates public/patients about medical and surgical eye care
  - Thousands of media-rich articles on all aspects of eye health: conditions, treatments, anatomy, news
  - Patient stories highlighting the real-world impact of ophthalmic care
- More than 500,000 page views **each week**
- Spanish version: OjosSanos



# EyeWiki® Overview

- Launched in 2010
- Goal – Improve ophthalmic education through global collaboration
- Resource for medical community and the public
- 600+ articles
- 5 MM+ annual page views
- 1,100+ registered authors
- 59% international visitors



The screenshot shows the EyeWiki website interface. At the top, there is the American Academy of Ophthalmology logo and the EyeWiki logo. A search bar is located in the top right corner. Below the navigation bar, the article title "Branch retinal vein occlusion" is displayed. A box highlights the article's contributors and editor information. The main content area includes a brief description of the condition and a table of contents. A fundus photograph of the retina is shown on the right side of the page, with two white circles highlighting specific areas of interest.

AMERICAN ACADEMY™ OF OPHTHALMOLOGY  
Protecting Sight. Empowering Lives.

EyeWiki™

Dan.Mummert.AAO Talk Preferences Watchlist Contributions Log out

Search

Main page Articles Getting Started Help Recent changes

Page Discussion Edit with form Edit Edit source History Delete Move Protect Watch Refresh

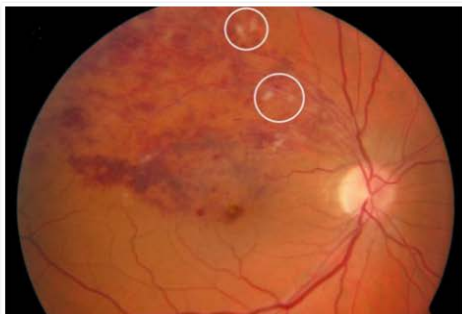
## Branch retinal vein occlusion

Original article contributed by: [Musa Abdelaziz, MD](#), [Mahdi Rostamizadeh](#), [Baseer Ahmad, MD](#)  
All contributors: [Musa Abdelaziz, MD](#)  
Assigned editor: [Musa Abdelaziz, MD](#)  
Review: Assigned status Update Pending by [Musa Abdelaziz, MD](#) on September 27, 2015.

Branch retinal vein occlusion is the most common retinal vein occlusion.

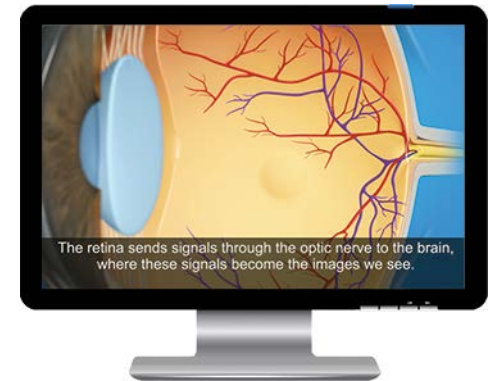
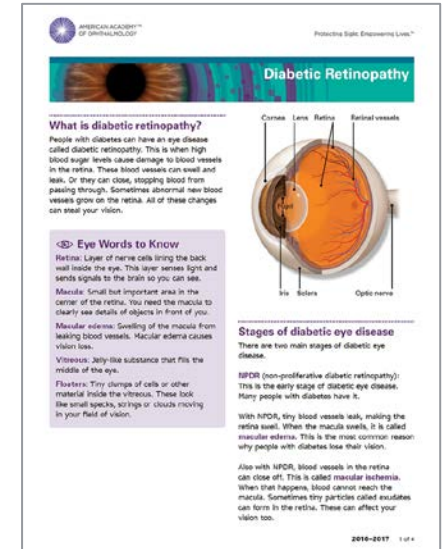
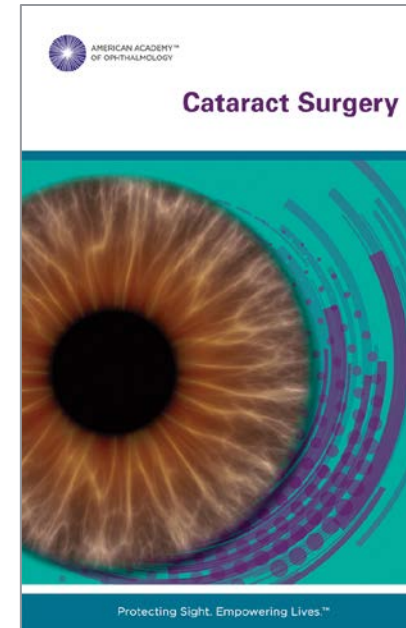
### Contents [hide]

- 1 Disease Entity
  - 1.1 Disease
  - 1.2 Classification
  - 1.3 Epidemiology
  - 1.4 Risk Factors
  - 1.5 Pathogenesis
- 2 Diagnosis
  - 2.1 History/Symptoms
  - 2.2 Physical examination/Signs
  - 2.3 Clinical diagnosis
  - 2.4 Diagnostic procedures
    - 2.4.1 Fluorescein angiography (FA)
    - 2.4.2 Optical coherence tomography (OCT)
  - 2.5 Laboratory test
  - 2.6 Differential diagnosis



# Patient Education Products

- Brochures, handouts and video content (more than 200 topics)
- Help manage patient knowledge/informed consent process
- Content supports healthcare literacy guidelines for ease of understanding
- English and Spanish for all titles




# Inter-professional Initiatives

- Multi-specialty education
  - *Physicians Guide to Eye Care*
  - Live eye care presentations
- Inter-professional eye care
  - Building best practices for informed consent
  - Wrong site/wrong IOL surgery
  - Activities for allied health and eye care teams
- Online News and Clinical Education
  - EyeNet<sup>®</sup> articles (open to public at 6 months)
  - Subspecialty Educational Centers
  - Clinical Information for medical students



AMERICAN ACADEMY<sup>™</sup>  
OF OPHTHALMOLOGY

EyeNet Magazine / March 2017



### CXL: The Road Ahead

Corneal cross-linking has been described as a “game changer” for keratoconus treatment. This month’s feature takes a look at preferred candidates and the standard protocol, along with evolving techniques, off-label uses, and malpractice concerns.

Read *EyeNet’s* Guide to MIPS 2017, which includes [Part 1: Know the Basics](#), [Part 2: How to Report Quality](#), and [Part 3: How to Report ACI](#).

March 2017

---

### Ophthalmic Pearls

#### Necrobiotic Xanthogranuloma

By Jonathan Hernandez-Siman, MD, and Rona Z. Silkiss, MD, FACS  
Edited by Sharon Fekrat, MD, and Ingrid U. Scott, MD, MPH

Though rare, this condition is important to recognize, as it may be associated with serious systemic diseases.

User Comments 0  
User Recommendations 0  
Views 8

---

### Clinical Update

#### HORV and Cataract Surgery, Part 2: Considering Alternatives to Vancomycin

By Linda Roach, Contributing Writer, interviewing David F. Chang, MD, Randy J. Epstein, MD, and Andre J. Witkin, MD

Is it time to stop using vancomycin? If so, what are the alternatives?

User Comments 0  
User Recommendations 0  
Views 10

Protecting Sight. Empowering Lives.™

# Inter-professional Activities



## A Guide for School Nurses



### > Common Eye Illnesses and Vision Problems in Children

This guide describes common eye and vision disorders in school-aged children to assist school nurses in identifying problems and taking appropriate action. Whenever an eye health or vision problem is suspected, the child should be referred to a pediatrician or family physician. The primary care physician will then evaluate the patient and, when appropriate, will refer the patient to a pediatric ophthalmologist or eye care specialist appropriately trained to treat pediatric patients.



AMERICAN ACADEMY™  
OF OPHTHALMOLOGY




AMERICAN ACADEMY™  
OF OPHTHALMOLOGY



National  
Association of  
School Nurses



American  
Association for  
Pediatric Ophthalmology  
and Strabismus



DEDICATED TO THE HEALTH OF ALL CHILDREN™

Brought to you by: The American Academy of Ophthalmology's Eyesmart Campaign in partnership with the American Association for Pediatric Ophthalmology and Strabismus.

Protecting Sight. Empowering Lives.™

# Inter-professional Initiatives

- Texts and Ebooks for medical students
  - *Basic Ophthalmology*
  - *Introducing Ophthalmology: A Primer for Office Staff*
  - *Ophthalmic Medical Assisting: An Independent Study Course*
- Academy Practice Guidelines available to public
  - *Preferred Practice Patterns*
  - Patient safety check list for surgical team
  - Procedures for pediatric eye evaluations

